

RESEARCH LETTERS

Volumetric Imaging of the Malar Fat Pad and Implications for Facial Plastic Surgery

The malar fat pad (MFP) establishes an important aesthetic norm easily identified as the cheek mound by the untrained eye. Although it is frequently manipulated as a part of contemporary facial aesthetic and reconstructive procedures,¹⁻⁴ a paucity of research exists that describes the static volumes and dynamic anatomic changes that occur with facial movement.

Methods. A prospective, institutional review board-approved, nonrandomized, case-control series included 11 subjects recruited from the Department of Otolaryngology, Stanford University, Stanford, California. The study was employed to determine the usefulness of a new technology in measuring volumetric norms of the MFP. We examined MFP volumes and compared volumes across sex and body mass index (BMI) (calculated as weight in kilograms divided by height in meters squared) using magnetic resonance imaging (MRI). In addition, conformational changes of the MFP were examined from a neutral to smiling posture. To our knowledge, this is the first study to demonstrate dynamic conformational changes in the MFP.

All the MRI investigations were performed with the subject in the supine position in a 0.5 T MRI scanner (GE Medical Systems, Waukesha, Wisconsin). The subjects were advised not to swallow and not to move while assuming a neutral or nonsmiling posture. Of the 11 subjects, 4 consented to undergo a second MRI while assuming a smiling posture. A multiplanar localizing sequence, followed in sagittal and coronal orientation using a turbo spin echo sequence, was performed for determining structure volumes. The total acquisition time was 10 minutes. Volumetric calculations were performed using a 3-dimensional (3D) image analysis application (Dextroscope, Volume Interactions, Republic of Singapore) to circumscribe areas, orient dimensions, and calculate volumes of the MFP. The MRI data were imported into the virtual reality environment and

rendered as a 3D object in a monoscopic or stereoscopic view using proprietary glasses. A line measurement tool was used to manually circumscribe the MFP in the sagittal plane per image slice. A volume tool automatically estimated the volume of the previously configured sagittal slices in cubic centimeters. The computation of the volume takes into account all voxels with a transparency value greater than 0.01 (transparency range, 0-1.0). The volume of the MFP per subject was calculated and compared across the case series in terms of sex, BMI, and differences between the right and left sides. The volumes in neutral position were compared with those in the smiling position per subject. The horizontal and vertical distances and anterior-posterior (A-P) depth of the MFP were compared in neutral and smiling positions.

The paired *t* test for normal continuous variables was used to test the null hypothesis that differences between groups (right- vs left-sided MFP volumes and sex differences) were equal to zero. All results of continuous variables are expressed as mean (SD). The Pearson correlation coefficient was used to associate BMI and total MFP volume.

Results. Demographic results for the 11 subjects in the study (7 men and 4 women) revealed a mean (SD) age of 33.5 (6.1) years (33.3 years for men and 33.8 years for women). The mean total MFP volume for men was 24.3 cm³ vs 17.9 cm³ in women (**Table 1**). Although there was a trend toward increased MFP volumes in men, the mean MFP showed no significant difference (*P* = .21).

The mean (SD) BMI was 25.1 (5.2) (27.7 for men and 20.7 for women). The BMI correlated with MFP volume

Table 2. Comparison of Malar Fat Pad Dimensions in Neutral and Smiling Positions^a

Dimension	Position		P Value
	Neutral	Smiling	
Volume, cm ³	15.4 ± 5.0	14.9 ± 6.0	.17
Length, mm			
Horizontal	47.3 ± 5.0	49.1 ± 3.0	.36
Vertical	38.1 ± 4.0	32.7 ± 3.0	.14
A-P	14.4 ± 3.0	12.4 ± 3.0	.03

Abbreviation: A-P, anterior-posterior.

^aData are presented as mean ± SD except where indicated otherwise.

Table 1. BMI and Malar Fat Pad (MFP) Volumes in Study Participants^a

Participants, No.	BMI	MFP Volume, cm ³		
		Right	Left	Total
Men (n = 7)	27.7 ± 5.0	12.2 ± 4.0	12.2 ± 4.0	24.4 ± 8.0
Women (n = 4)	20.7 ± 2.0	9.0 ± 3.0	9.0 ± 3.0	18.0 ± 6.0
All (N = 11)	25.1 ± 5.0	11.0 ± 4.0	11.0 ± 4.0	22.0 ± 8.0

Abbreviation: BMI, body mass index (calculated as weight in kilograms divided by height in meters squared).

^aData are presented as mean ± SD.

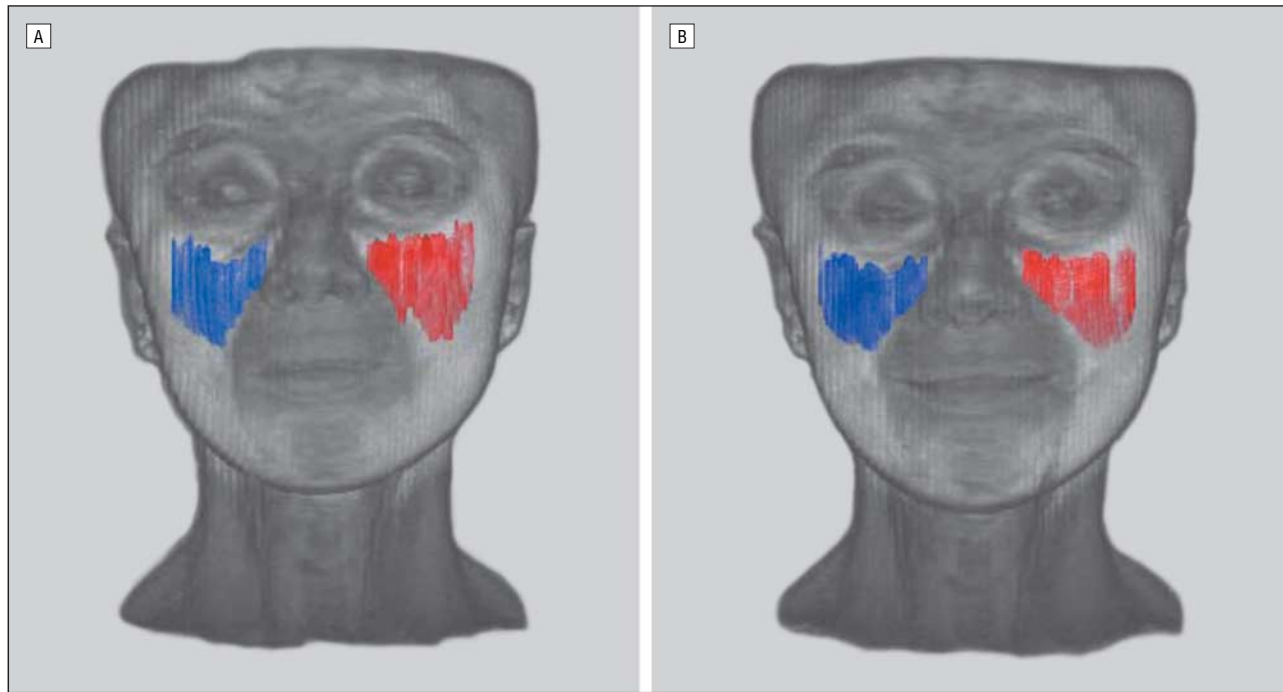


Figure. Volumetric representation of the malar fat pad (MFP) in neutral and smiling positions. Composite image showing a representative subject with superimposed 3-dimensional representations of the MFP in (A) the neutral position and (B) smiling position. The right MFP is represented in blue, the left in red. Note the gross change in MFP morphologic traits with smiling, with reduction in vertical height being most evident.

(Pearson correlation coefficient, 0.76). As BMI increased, the relative volume of the MFP also increased. There was no statistical difference when comparing left-sided vs right-sided MFP volumes per individual (Table 1).

To measure any changes in MFP dimensions with movement, 4 subjects were measured in the smiling position. There was no change in MFP volume as measured in neutral and smiling positions (Table 2). A minimal increase in horizontal length (47.3 [5.0] mm to 49.1 [3.0] mm) and a trend toward decrease in the vertical dimension (38.1 [4.0] mm to 32.7 [3.0] mm) and shortening in the A-P dimension (14.4 [3.0] mm to 12.4 [3.0] mm) in the smiling position were noted (Table 2). The volume of the MFP was consistent in the neutral and smiling positions.

Comment. Our preliminary study demonstrates a novel technique for measuring the volume of the MFP. Furthermore, we demonstrate conformational changes in the MFP shape during dynamic positional changes in facial expression (Figure). In the literature,⁵⁻⁷ there are only a few articles dealing with the evaluation of the facial fat deposits with MRI, none evaluating the MFP alone. These studies did not discriminate BMI with MFP volume, nor did they evaluate dynamic changes in position.

In the current study, we demonstrate a correlation between BMI and MFP volume. We note a trend toward increased volume in men compared with women, although this did not reach statistical significance ($P = .21$). A more appropriate comparison is that of BMI and MFP volume, for which a correlation was found. It remains to be seen if changes in BMI within a given subject result in changes in MFP volume. Another novel finding was changes of MFP conformation with smiling. The validity of our measure-

ments of the MFP volume is bolstered by our finding that measured volumes of the MFP remain consistent in the neutral and smiling positions. As visualized in the Figure, the MFP grossly shortens in the vertical dimension with smiling. We also show minimal lengthening in the horizontal direction and shortening in the A-P direction with smiling. Because the MFP volume does not change with position, we assume that the volume is distributed over a wider horizontal area. Our measurement did not detect this, but it may be secondary to our small sample size. Further studies in facial fat deposits using this technique may answer this question.

Our study shows a novel approach to evaluate the MFP in subjects. There was no notable difference in volumes when comparing left vs right sides, demonstrating internal consistency. However, MFP volume was associated with increased BMI. Comparing neutral vs smiling postures, changes in MFP conformation were found. Such studies may help us understand the complexity of this dynamic structure, as well as changes in the MFP with aging, and possibly guide surgical planning.

Jose E. Barrera, MD
Sam P. Most, MD

Correspondence: Dr Barrera, Division of Facial Plastic and Reconstructive Surgery, 801 Welch Rd, Stanford, CA 94305 (jebarrera@yahoo.com).

Financial Disclosure: None reported.

1. Moelleken BR. Midfacial rejuvenation. *Facial Plast Surg.* 2003;19(2):209-222.
2. Williams EF III, Vargas H, Dahiya R, Hove CR, Rodgers BJ, Lam SM. Midfacial rejuvenation via a minimal-incision brow-lift approach: critical evaluation of a 5-year experience. *Arch Facial Plast Surg.* 2003;5(6):470-478.
3. Most SP, Mobley SR, Larrabee WF Jr. Anatomy of the eyelids. *Facial Plast Surg Clin North Am.* 2005;13(4):487-492, v.

- Lam SM, Glasgold MJ, Glasgold RA. *Complementary Fat Grafting*. Philadelphia, PA: Lippincott Williams & Wilkins; 2007.
- Gosain AK, Klein MH, Sudhakar PV, Prost RW. A volumetric analysis of soft-tissue changes in the aging midface using high-resolution MRI: implications for facial rejuvenation. *Plast Reconstr Surg*. 2005;115(4):1143-1145.
- Kahn JL, Wolfram-Gabel R, Bourjat P. Anatomy and imaging of the deep fat of the face. *Clin Anat*. 2000;13(5):373-382.
- Loukas M, Kapos T, Louis RG Jr, Wartman C, Jones A, Hallner B. Gross anatomical, CT and MRI analyses of the buccal fat pad with special emphasis on volumetric variations. *Surg Radiol Anat*. 2006;28(3):254-260.

A Follow-up Study of the Monarch Adjustable Implant for Correction of Nasal Valve Dysfunction

Dysfunction of the nasal valve is becoming an increasingly common cause of nasal airway obstruction as the general population ages. Senile nasal changes are becoming the most common reason for valve dysfunction.¹ Because the nasal valve represents the smallest segment of the respiratory tract in cross-sectional area, even small changes in size or wall support can have a profound affect on nasal airflow.² Consistent correction of the nasal valve has proved challenging for surgeons, where choice and proper execution of the appropriate surgical technique are critical for success. Still, consistent results can be evasive even for the experienced surgeon.

The Monarch implant (Hanson Medical, Kingston, Washington) is designed to function like the cartilaginous butterfly graft or effectively as an adjustable implanted Breathe-Right dilator (CNS Inc, Minneapolis, Minnesota). It corrects valve obstruction at both the internal and external levels for both dynamic and static dysfunction.³ The Monarch implant is a bimaternal device with an expanded polytetrafluoroethylene vs reinforced silicone outer casing surrounding a malleable titanium core. The malleability of the device allows the surgeon to fine-tune the airway to obtain an optimal valve area with aesthetic balance. Adjustments can be made during surgery or after surgery in the physician's office.

Methods. A total of 16 patients underwent implantation by techniques previously described.³ Two patients had concurrent septoplasty, whereas 5 had turbinate

reductions. Nine patients were followed for a 6-month period. Valve collapse was diagnosed by way of physical examination, acoustic rhinomanometry (Rhinometrics; Interacoustics AS, Assens, Denmark), inspiratory nasal base view photographs, and a subjective questionnaire. The patients' mean age was 66 years. Data were obtained before surgery and at 1-month intervals after surgery.

Results. At 1 month after surgery, questionnaire data revealed a great improvement in daytime and nighttime nasal airway ratings. The snoring rating dropped substantially, with a slight drop in apnea, a slight increase in olfactory function, and a decreased propensity for daytime mouth breathing. Inspiratory base view photographs showed a pronounced increase in the dynamic area of the external valve, whereas rhinomanometry revealed a substantially improved static internal nasal valve area (**Table**).

At 6 months after surgery, questionnaire ratings demonstrated slight improvements over the 1-month scores except for a slight return in mouth breathing. Rhinomanometry data revealed further improvement in the internal nasal valve area, whereas base view photographs revealed a decrease in external nasal valve stability (**Table, Figure**).

Comment. Questionnaire results revealed stability at 6 months compared with the 1-month data. Daytime nasal airway, nighttime nasal airway, and olfactory function further improved slightly, whereas snoring improvement remained stable. Apnea decreased quite substantially during this period. This is probably attributable to a decrease in nasal edema at 6 months with further airway improvement. Mouth breathing returned somewhat at 6 months. These patients were habitual mouth breathers and apparently returned to mouth breathing even with an improved nasal airway.

At 6 months, static internal nasal valve areas increased, whereas external nasal valve dynamic areas decreased. A decrease in postoperative edema is again most likely the reason for both of these changes. Decreasing edema would further enlarge the internal valve area. Conversely, alar edema would have a stenting affect on the external nasal valve, imparting dynamic stability at this

Table. Patient Questionnaire, Static Acoustic Rhinomanometry, and Dynamic Photographic Data^a

Questionnaire Variable	Nasal Airway ^b		Snoring ^c	Apnea ^c	OF ^b	MB, % ^d	Rhinomanometry, Internal NV Static Area, cm ² (Increase, %)		Photographic Data, External NV Dynamic Area Increase, %	
	Day	Night					Right	Left	Right	Left
	Before surgery	4.5					2.8	7.1	4.0	6.3
After surgery										
1 mo	8.3	7.4	3.2	3.2	7.7	16	0.75 (64)	0.79 (133)	139	99
6 mo	9.1	8.0	3.2	1.0	9.0	30	0.91 (99)	0.86 (152)	70	60

Abbreviations: MB, mouth breathing; NR, not reported; NV, nasal valve; OF, olfactory function.

^aData are presented as mean scores on a scale of 1 to 10 except where indicated.

^bOn a scale of 1 to 10 in which 10 is best.

^cOn a scale of 1 to 10 in which 10 is worst.

^dDaytime respiration.